

Colon cancer presenting as a hepatic mass in pregnancy: A case report and review of the literature

N C Ngene,¹ Dip HIV Man (SA), MMed (FamMed), FCOG (SA), MMed (O&G); E F Orie,¹ FCOG (SA), MMed (O&G); T D Naidoo,¹ FCOG (SA); J Moodley,² FCOG (SA), FRCOG, MD

¹ Department of Obstetrics and Gynaecology, Grey's-Edendale Hospitals Complex, Pietermaritzburg, South Africa

² Women's Health and HIV Research Group, Nelson R Mandela School of Medicine, University of KwaZulu-Natal, Durban, South Africa

Corresponding author: N C Ngene (ngenenc@gmail.com)

The incidences of hepatic masses and colon cancer in pregnancy are low. The clinical features of each can mimic those of pregnancy, thereby posing a diagnostic challenge to clinicians, particularly when the clinical scenario is complicated by HIV infection. This report illustrates such diagnostic difficulties, and the need to offer diagnostic colonoscopy to HIV-infected pregnant women who present with both a hepatic mass and minor gastrointestinal symptoms. It also highlights an approach to the management of colon carcinoma presenting as a hepatic mass in pregnancy.

S Afr J OG 2014;20(2):60-62. DOI:10.7196/SAJOG.756



Colorectal carcinoma (CRC) in pregnancy is rare, with an incidence of 1/13 000.^[1] The similarity of its symptoms to those of pregnancy can cause a delay in making a diagnosis of CRC. This delayed diagnosis may result in the disease presenting at an advanced stage, which occasionally manifests as a hepatic mass. Although hepatic masses are rare in pregnancy,^[2] their exact incidence is difficult to establish as many are asymptomatic or their symptoms may be attributed to the pregnancy.^[3] Benign hepatic masses are commoner than malignant types in pregnancy,^[2] making diagnosis of a metastatic hepatic mass a challenge.

CRC is uncommon in patients aged <40 years.^[4] Young patients with CRC are more likely than the older age group to have major risk factors such as Lynch syndrome, familial adenomatous polyposis or longstanding inflammatory bowel disease. However, patients with these risk factors account for only a small proportion of CRCs diagnosed in pregnancy,^[4] making an accurate diagnosis more challenging in young age groups. We review a case of colon cancer presenting as a hepatic mass in pregnancy and the role of colonoscopy in its diagnosis.

Case report

A 33-year-old woman was referred to our tertiary hospital complex at 31 weeks' gestation with a history of severe right upper quadrant (RUQ) pain and abnormal liver function test (LFT) results. This was her third pregnancy and her previous two deliveries had been uneventful. She had had four previous antenatal clinic visits beginning at 20 weeks' gestation. She was HIV-infected (diagnosed in 2004), and had become eligible for antiretroviral therapy for her own health in October 2010. In June 2011, while on antiretroviral therapy, she had an undetectable viral load and a CD4⁺ count of 274 cells/ μ l.

Further history revealed that the RUQ pain had started 2 weeks earlier. The pain was gradual in onset, non-radiating and unrelated to meals. There was associated weight loss, night sweats

and diarrhoea, but no history of loss of appetite, vomiting, fever, jaundice, passage of bloody or mucoid stool, body swelling or vaginal bleeding. She had completed 6 months of treatment for pulmonary tuberculosis in 2011 and there was no family history of malignancy or chronic illness.

Clinical examination revealed an ill-looking woman with generalised lymphadenopathy, visible superficial abdominal vessels, and an enlarged liver that was palpable 10 cm below the costal margin, smooth and tender. There were no other palpable masses except for a viable singleton pregnancy estimated to be about 30 weeks' gestation. Vaginal examination revealed no untoward clinical features and there were no signs of preterm labour. A diagnosis of a hepatic mass in pregnancy was considered, and she was admitted for management by a multidisciplinary team. Her LFT results and alpha-fetoprotein level (241 μ g/l) were elevated. A hepatitis screen was negative, and the findings on an amoebic gel diffusion test and stool microscopy were normal. Hypochromic microcytic anaemia (with normal iron study, folate and vitamin B₁₂ levels) was detected and the patient was given a blood transfusion of 2 units of packed cells. The clotting profile, blood sugar and renal function test results were within the normal range. A chest radiograph showed an elevated dome of the right diaphragm, and an abdominal ultrasound scan revealed an inhomogeneous echogenic vascular solid mass (10.5 \times 10.7 \times 12 cm) occupying the right lobe of the liver and encasing the portal vein, with distension of the inferior vena cava, splenic vein and right renal vein. Ultrasonography also demonstrated lobulated echogenic masses with central radiating arterial vessels, as well as peripheral vessels, specifically in the large lesion in the right lobe of the liver. These findings were inconclusive and magnetic resonance imaging (MRI) was therefore undertaken.

MRI of the abdomen showed minimal ascites, hepatosplenomegaly, and several lesions in the liver parenchyma and in the spleen. The larger lesions in the right and left lobes of the liver showed features of central necrosis with no haemorrhage (Fig. 1). The right liver mass was noted

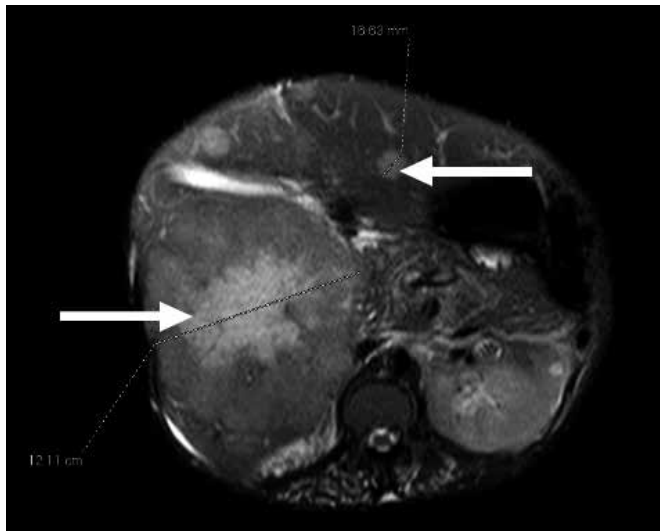


Fig. 1. Magnetic resonance imaging of the abdomen revealing multiple hepatic masses (arrows), with the largest mass showing central necrosis.

to be compressing the portal vein and common bile duct. Enlarged para-aortic nodes were also noted, while the gallbladder, bile ducts and pancreatic duct appeared normal. Experienced radiologists reviewed the images, and the following differential diagnoses were considered: adenoma, focal nodular hyperplasia, hepatocellular carcinoma, secondary metastatic lesions and hepatic/splenic lymphoma.

Biopsy of the liver lesion was deferred until after delivery. At 34 weeks' gestation, a decision was made to deliver the fetus because of worsening pain. An elective caesarean section (CS) was performed because of the vascular hepatic mass, and a healthy male baby weighing 2 320 g was delivered. Because of the risk of rupturing the mass, the abdomen was not explored or the liver inspected or palpated during the CS. The patient had an uneventful postoperative recovery and was discharged on day 6. An ultrasound-guided liver biopsy was carried out 3 weeks after the CS, and histological examination showed a moderately differentiated mucinous adenocarcinoma with a tubular growth pattern. A colonoscopic biopsy subsequently confirmed cancer of the colon. At laparotomy the cancer was found to be inoperable, and a defunctioning ileostomy was done and palliative chemotherapy planned.

Discussion

Establishing a diagnosis of CRC presenting as a liver mass in pregnancy requires a high index of suspicion, while at the same time excluding other possible causes^[2] of such a lesion. The risk of metastasis, colon perforation and bowel obstruction is higher in pregnant women with CRC than in the general population. This may be attributed to the immunosuppressive state of pregnancy.^[5] HIV infection in pregnancy increases immune dysfunction and probably explains why our patient had early spread of the cancer to the liver with minor gastrointestinal symptoms.

Investigations that aid the diagnosis of CRC are measurement of serum carcinoembryonic antigen (CEA) levels, abdominal imaging and colonoscopy, with a biopsy establishing a definitive diagnosis. Although serum levels of CEA are normal or marginally elevated in pregnancy, it is used as a tumour marker as in non-pregnant patients.^[4] The higher the level, the higher the risk of disseminated disease and recurrence. A CEA value obtained before surgery also serves as a baseline to monitor response to treatment.

Although colonoscopy aids the diagnosis of CRC, it carries an increased risk in pregnancy and should be done only when there is a strong indication, preferably in the second trimester. The risks include exposure of the fetus to teratogenic medications, and maternal hypotension due to compression of the inferior vena cava. Apart from a diagnostic role, imaging techniques also help in the staging of the disease. Abdominal ultrasound is able to detect macrometastatic lesions in the liver, while endorectal ultrasound provides excellent images of the rectal wall. In our case, MRI was undertaken because of inconclusive findings on ultrasound of the abdomen. The superiority of MRI over conventional ultrasound in the characterisation of liver lesions has been reported^[6,7] previously. When ultrasound and MRI are used for the diagnosis of liver pathology, their sensitivities are 40 - 70% and 68 - 90%, respectively.^[7]

A diagnostic work-up for hepatic masses in pregnancy reported by Cobey and Salem^[3] did not include hepatic masses caused by secondary metastatic lesions. Furthermore, the indications for endoscopy in pregnancy^[8] are not representative of all the clinical scenarios that might require colonoscopy. For example, the diagnosis of CRC in our patient was only suspected after liver biopsy showed adenocarcinoma, following which colonoscopy-directed biopsy confirmed the diagnosis. This case illustrates that a hepatic mass with minor (non-bleeding, non-chronic) gastrointestinal symptoms in an HIV-infected pregnant patient should be regarded as an indication for colonoscopy, particularly when imaging techniques fail to suggest a diagnosis with reasonable certainty.

Once a diagnosis of CRC is made during pregnancy, the patient should be managed by a multidisciplinary clinical team. Further management depends on the gestational age at diagnosis, the stage of the disease, elective versus emergency presentation, the patient's wishes, and complications of the tumour or the pregnancy. If CRC is diagnosed before 20 weeks' gestation, surgical resection of the tumour can be performed with or without termination of pregnancy, depending on the patient's preference. When CRC is diagnosed after 20 weeks' gestation, it is recommended that surgery be delayed until fetal viability. In stages II or III CRC, adjuvant chemotherapy with 5-fluorouracil improves survival.^[5] Chemotherapy is contraindicated in the first trimester because of the risk of teratogenicity, but it may be administered during the second and third trimesters to consenting patients. 5-fluorouracil and oxaliplatin are chemotherapeutic combinations that have been used successfully in pregnancy after the first trimester. Although radiotherapy can be used to treat rectal cancer, it carries a risk of radiation to the fetus and is therefore not generally recommended in pregnancy. Even when initiated after childbirth, pelvic radiotherapy carries a risk of damage to the ovaries, and patients' fertility wishes therefore need to be explored prior to therapy.

CRC does not influence the mode of delivery unless the tumour is obstructing the birth canal, in which case delivery will be by CS. Resection of the tumour can be undertaken during CS, but vascular engorgement of the pelvis may increase surgical risk. At the time of CS in the case presented, a definitive diagnosis had not been established and tumour resection was not considered. Also, metastatic lesions in the liver will usually show minimal vascular enhancement.^[9] Because of increased vascularity of the hepatic lesions detected in our patient, the differential diagnosis of a liver metastasis was less favoured than other possibilities, and the surgeons decided that the abdomen should not be explored during the CS. This may be considered an omission, implying that

a major lesson from this report is that inspection of the liver and/or exploration of the abdomen by the surgeons, with gentle handling of tissues, would have helped in earlier establishment of the diagnosis.

There is no evidence to suggest that CRC has direct adverse effects on the fetus, although metastasis to the placenta and the fetus has been reported,^[10] with evaluation of the placenta after delivery being advised. In our case there was no evidence of a fetal effect. While the prognosis for CRC in pregnancy is poor because of the delay in diagnosis, the 5-year survival rate in these cases is similar to that in the general population.^[5]

Conclusion

In conclusion, HIV-infected pregnant patients presenting with a hepatic mass and minor gastrointestinal symptoms should be offered colonoscopy to exclude advanced CRC.

1. Woods J, Martin JJ, Ingram F, Odom C, Scott-Conner C, Rhodes R. Pregnancy complicated by carcinoma of the colon above the rectum. *Am J Perinatol* 1992;9(2):102-110. [<http://dx.doi.org/10.1055/s-2007-994680>]
2. Athanassiou AM, Craig SD. Liver masses in pregnancy. *Semin Perinatol* 1998;22(2):166-177. [[http://dx.doi.org/10.1016/S0146-0005\(98\)80049-9](http://dx.doi.org/10.1016/S0146-0005(98)80049-9)]
3. Cobey FC, Salem RR. A review of liver masses in pregnancy and a proposed algorithm for their diagnosis and management. *Am J Surg* 2004;187(2):181-191. [<http://dx.doi.org/10.1016/j.amjsurg.2003.11.016>]
4. Cappell MS. Colon cancer during pregnancy. *Gastroenterol Clin North Am* 2003;32(1):341-383. [[http://dx.doi.org/10.1016/S0889-8553\(02\)00066-3](http://dx.doi.org/10.1016/S0889-8553(02)00066-3)]
5. Longo SA, Moore RC, Canzoneri BJ, Robichaux A. Gastrointestinal conditions during pregnancy. *Clin Colon Rectal Surg* 2010;23(2):80-89. [<http://dx.doi.org/10.1055/s-0030-1254294>]
6. Albrecht T, Hohmann J, Oldenburg A, et al. Detection and characterisation of liver metastases. *Eur Radiol* 2004;14(Suppl. 8):25-33.
7. Assy N, Nasser G, Djibre A, Beniashvili Z, Elias S, Zidan J. Characteristics of common solid liver lesions and recommendations for diagnostic workup. *World J Gastroenterol* 2009;15(26):3217-3227. [<http://dx.doi.org/10.3748/wjg.15.3217>]
8. ASGE Standard of Practice Committee. Guidelines for endoscopy in pregnant and lactating women. *Gastrointest Endosc* 2012;76(1):18-24. [<http://dx.doi.org/10.1016/j.gie.2012.02.029>]
9. Rockey DC, Caldwell SH, Goodman ZD, et al. Liver biopsy. *Hepatology* 2009;49(3):1017-1044. [<http://dx.doi.org/10.1002/hep.22742>]
10. Rothman LA, Cohen CJ, Astarloa J. Placental and fetal involvement by maternal malignancy: A report of rectal carcinoma and review of the literature. *Am J Obstet Gynecol* 1973;116(7):1023-1034.